

CP NO 8957

Sindhu  
Kochi

Dep. Fibroid uterus

DR. NAMBIAR'S ULTRASOUND SCAN CENTRE

KARUNA, CHITTOOR ROAD, KOCHI 16

Ph: 364623/352833

ULTRASOUND, ECHOCARDIOGRAPHY & WHOLE BODY COLOUR DOPPLER SCAN

PATIENT'S NAME : Mrs. SINDHU

November 29, 2000

Consultant : Dr. AGNES GEORGE

Many thanks for the referral.

REPORT

Ultrasound study of the uterus and adnexa

(Trans.abd. & Trans.vaginal scan)

Uterus : measures about 6.5x3.7cms in diameter. Uterus is normal in size and shape. Endometrial lining is within normal limits. 2 irregular low echogenic solid areas are seen in the uterine walls, varying in size from 1 to 1.2cms. No mass lesion seen in the adnexa.

Cervix is normal

Ovaries : Right ovary measures about 3.6x3.1cms in diameter and the left ovary about 3.5x3cms in diameter. Multiple cystic areas are seen in the right ovary and similar multiple cystic areas are seen in the left ovary, each measuring about 7x8mm in diameter.

Tubes No abnormal thickening or dilatation noted.  
No fluid is seen in the cul-de-sac.

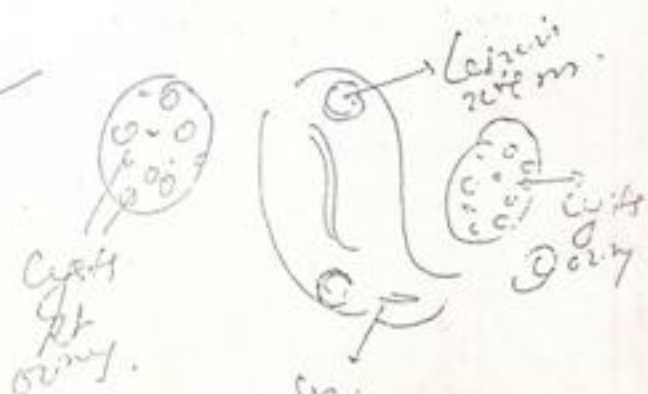
Urinary bladder : Normal lumen and walls.

IMPRESSION :

1. 2 irregular low echogenic solid areas in the uterine walls, varying in size from 1 to 1.2cms - small fibroids or adenomyosis.
2. Multiple cystic areas in the right ovary and similar multiple cystic areas in the left ovary, each measuring about 7x8mm in diameter - follicles or cystic ovaries.

Suggest clinical correlation.

Dr. DAMODARAN NAMBIAR.MD,DMRD  
(Consultant Radiologist)



DR. NAMBIAR'S ULTRASOUND SCAN CENTRE

KARUMA, CHITTOOR ROAD, KOCHI 16

Ph: 384623/352833

ULTRASOUND, ECHOCARDIOGRAPHY & WHOLE BODY COLOUR DOPPLER SCAN

PATIENT'S NAME : Mrs. SINDHU VENU

April 30, 2001

Consultant : Dr. S. KRISHNAKUMAR

Many thanks for the referral.

REPORT

Ultrasound study of the uterus and adnexa

(Trans.abd. & Trans.vaginal scan)

Uterus : measures about 6.2x3.3cms in diameter. Uterus is normal in size and shape. Endometrial lining is within normal limits. No mass lesion seen in the uterus or adnexa.  
Cervix is normal

Ovaries : Normal. right ovary measures about 3.5x3cms in diameter and the left ovary about 2.5x3.2cms in diameter. Multiple cystic areas are seen in both ovaries, varying in size from 7 to 5mm.

Tubes No abnormal thickening or dilatation noted.  
No fluid is seen in the cul-de-sac.

Urinary bladder : Normal lumen and walls.

IMPRESSION :

1. No space occupying lesion in the uterus or adnexa.
2. Multiple cystic areas in both ovaries, varying in size from 7 to 5mm - follicles or cystic ovaries.

Suggest clinical correlation.

Dr. DAMODARAN NAMBIAR, MD, DMRD.  
(Consultant Radiologist)

*[Signature]*

